



Title	Prognostic Evaluation of Small Sized Lung Cancer Following Surgery
Author(s)	Tomita, Masao; Koga, Yasunori; Shibata, Koichiro; Onizuka, Toshio; Sacoda, Koichiro; Matsumoto, Kazuhisa; Maeda, Takami; Hamasuna, Shigehito; Wake, Norio; Ichinose, Yukito; Ayabe, Kimihiro; Nakamura, Yuzuru; Tsuji, Yasukuni
Citation	Acta medica Nagasakiensia. 1979, 24(1-4), p.40-47
Issue Date	1979-10-25
URL	<a href="http://hdl.handle.net/10069/15614">http://hdl.handle.net/10069/15614</a>
Right	

This document is downloaded at: 2016-03-05T10:11:21Z

## Prognostic Evaluation of Small Sized Lung Cancer Following Surgery

Masao TOMITA\*, Yasunori KOGA\*, Koichiro SHIBATA\*,  
Toshio ONIZUKA\*, Koichiro SACODA\*,  
Kazuhisa MATSUMOTO\*, Takami MAEDA\*,  
Shigehito HAMASUNA\*, Norio WAKE, Yukito ICHINOSE\*,  
Kimihiro AYABE\*\*, Yuzuru NAKAMURA\*\*, Yasukuni TSUJI\*\*

\* *The Second Department of Surgery,  
Miyazaki Medical College*

\*\* *The first Department of Surgery  
Nagasaki University School of Medicine*

Received for publication, March 10, 1979

The prognosis after surgical treatment for so-called small sized lung cancer which was less than 2 cm in diameter was mainly evaluated in this study. From the present study, the prognosis after surgery of a small sized lung cancer which less than 1.5 cm diameter of tumor mass could not be necessarily satisfactory because of appearance of recurrence and metastasis after surgical treatment.

We concluded that the term of lung cancer in early stage meant permanent curability from prognostic view of long term follow-up. Nevertheless, a small sized lung cancer from 1.0cm to 1.5cm in diameter of tumor mass did not necessarily result in complete cure rate.

Thirteen cases with a small sized carcinoma ranging from 1.0 cm to 2.0 cm in size were subjected to evaluate the prognosis after surgery.

The distant metastasis occurred in 45.5% of them except 2 deaths unrelated to carcinoma. Histological pattern of primary tumor, in which distant metastatic focus was seen in relatively early stage following surgery, showed adenocarcinoma except one of squamous cell carcinoma.

Interestingly enough, a case with lung cancer of small cell carcinoma survived more than 6 years after surgery without any recurrence.

Furthermore, the degree of immunological host response with small sized lung cancer was studied by skin reaction against PPD. In addition, histological findings with regard to

---

\*富田 正雄・古賀 保範・柴田紘一郎・鬼塚 敏男・迫田耕一朗・松本 和久・前田 隆美・浜砂 重仁  
和気 典雄・一瀬 幸人・\*\*綾部 公懿・\*\*中村 譲・\*\*辻 泰邦

tissue reaction of surrounding carcinoma in surgical specimen and histiocytosis in resected lymphnodes have been compared with its prognosis. The further study with reference to immunity for tumor-bearing host is necessary to certify some factors associated with its prognosis.

## INTRODUCTION

Recently the results in treatment for carcinoma is far prominent, reflecting a technical improvement of diagnosis to detect in early stage.<sup>1)2)</sup>

Therefore, its prognosis after early treatment is apparently better than that after late one.

It is obvious that no any recurrence and metastasis following surgical resection occur in terms of early cancer of the lung theoretically. Meanwhile, it is impossible to decide for early cancer of the lung preoperatively because of no clinical criteria experienced in a large number of follow-up study for the prognosis of early lung cancer. In hilar type, the definition of early cancer is established by histological findings in which cancerous invasion is never seen beyond submucosal layer. In peripheral type, the lung cancer of less than 2 cm in diameter of tumor size is called as a small sized lung cancer, but this is not in accordance with the definition of prognostic early cancer of the lung.

The aim of this study is to certify whether the prognosis of small sized lung cancer is satisfactory or not and to determine the maximal limit of tumor size which ensure a permanent curability.

## CLINICAL MATERIAL

Thirteen cases with lung cancer of a small size of less than 2 cm in diameter are subjected to analyze the prognosis following surgical treatment.

Ten cases of these 13 cases were male and the remaining 3 cases were female and male is preferable to female for occurrence of lung cancer.

The age of these 13 cases ranged from 40 to 68. According to age distribution, 8 cases were 40 years old, 1 case was 50 years old and 4 cases were 60 years old as shown in Table 1.

With regard to histological pattern of lung cancer, 2 cases were squamous cell carcinoma, 10 cases were adenocarcinoma and 1 was undifferentiated carcinoma. The chance which enable to detect asymptomatic lung cancer was either mass examination in 7 cases or incidental detection at the time of treatment for other disease in 1 case. The remaining 5 cases have several complaints such as fever, cough, sputum and chest pain in spite of a small sized cancer.

The several factors with regard to the prognosis after surgery were evaluated on 8 cases survived over periods of more than 5 years.

The interval from onset to surgical treatment is not necessarily short, 3 cases had

within 4 months duration, 6 cases within 8 months duration and 2 cases within 12 months duration respectively.

Furthermore, 2 cases with small sized lung cancer had beyond 12 months duration. From these analysis, it is documented that the early treatment is mandatory to improve its prognosis.

Four cases of these 13 cases had tumor shadows as large as 1.0 cm to 1.5 cm and the remaining 9 cases had 1.5 cm to 2.0 cm in diameter. As a consequence, none among them had less than 1.0 cm in diameter of tumor.

From radiological finding on chest xp, hilar type was observed in 3 cases, although peripheral type in 10 cases. The relationship of smoking index by Binkman was obscure in this series.

## RESULT

Of 13 cases with a small sized lung cancer of less than 2 cm in diameter, 10 cases were male and 3 cases were female. According to age distribution, 8 cases out of 13 cases were in the age of 40 to 49 years. It seems that age of patients diagnosed with small sized lung cancer are younger than that with large sized as shown in Table 1.

The detection of a small sized lung cancer requires the meticulous examination among asymptomatic younger group.

However, 5 cases of these 13 cases had some respiratory complaints without any specificity related to lung cancer.

From the analysis of the interval from onset to operative treatment, a considerable periods as much as average of 8 months, needed to treat it. Although 3 cases had less than 4 months duration until surgical treatment, 6 cases had 8 months duration, 2 cases 12 months duration and 2 cases more than 12 months duration.

It is emphasized that short interval from onset to surgical treatment is mandatory for improvement of postoperative prognosis. In the comparison of the size of carcinoma at the time of operation, 4 cases revealed 1.0 cm to 1.5 cm in diameter and 9 cases showed 1.5 cm to 2.0 cm in diameter but none experienced in detection of less than 1 cm in diameter of tumor size.

By the finding of chest roentogenogram, the peripheral type of lung cancer was observed in 10 cases of these 13 cases and the remaining 3 cases presented the hilar type by roentogenogram. The majority of those cases with small sized carcinoma were discovered as those with more than 1 cm in diameter of tumor size and it is documented that early treatment soon after detection of abnormal shadow on chest xp is the most important prerequisite to enhance the cure rate for lung cancer.

The diagnostic procedures of these cases were presented in Table 2. From the

**Table 1.** Cases with small size lung cancer.

Age	Male	Female
40yrs~	6	2
50	1	
60~	3	1
total	10	3

**Table 2.** Effectiveness of diagnostic procedures (diagnosed cases/diseased cases)

type of histology	Tomography	Angiography PA	BA	bronchography	endoscopy	cytology
Sg. Ca.	2/2	1/2	2/2	2/2	1/2	2/2
Adeno Ca.	10/10	8/10	5/10	5/10	8/10	5/10
Small cell Ca.	1/1		1/1	1/1		1/1

PA : pulmonary artery    BA : bronchial artery

finding of roentgenogram, the special features of malignant tumor has been revealed by notching of irregular circumference and unhomogenous density of tumor shadow.

However, the stenosis, displacement and interruption of the bronchus on bronchogram were the most important diagnostic finding for hilar type despite of small sized lung cancer.

Furthermore, positive finding of cytological examination from sputum was obtained in 8 cases of these 13 cases. Therefore, cytological examination of sputum or by bronchial brushing provides the more definitive diagnosis for small sized lung cancer.

According to operative methods employed, 11 cases underwent radical lobectomy and one of these 11 cases had lobectomy with bronchoplastic procedures. Of the remaining 2 cases, one underwent pneumonectomy and combined pleurectomy, the other partial resection of the diaphragma. On the postoperative course, adjuvant therapy combined with chemotherapy of mitomycine C was used in all 13 cases and in one case radiation therapy was added to these chemotherapy.

By follow-up study over 5 years duration, most of recurrence or metastasis occurred within two years interval, namely, bone metastasis in 2 and skin metastasis in 1 within 2 years interval and also the lung, the bone, the adrenal and the brain metastasis in 1 at the time of 4th year following operation.

The prognosis of lung cancer after surgical treatment has related to occurrence of distant metastasis which at least will be mostly seen within 2 years following surgery.

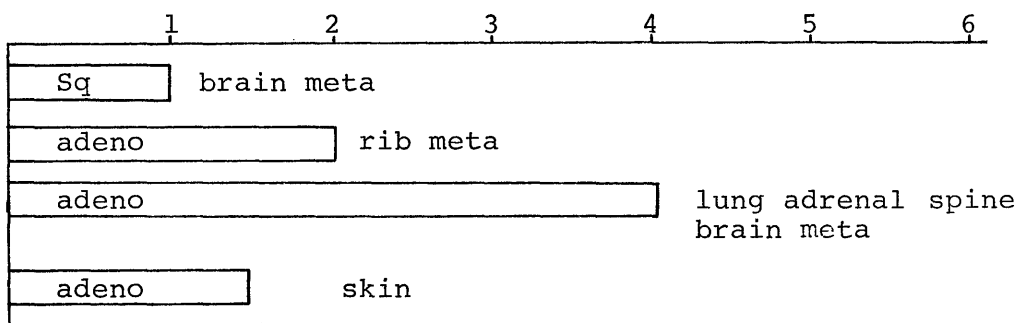


Fig 1. Cases with recurrence and metastasis

Hilar metastasis was observed in 4 cases of these 13 cases and vascular invasion in microscopic examination of surgical specimen was confirmed in 4 cases with even a small sized carcinoma. (Fig. 2) The prognosis of those with both hilar metastasis and vascular invasion by histological examination was significantly poor. However, 2 cases with vascular invasion survived until 5 years duration after surgery, reflecting the efficacy of chemotherapy.

Moreover, immunological capacity of host was evaluated by histological pattern of sinus histiocytosis in resected lymphnodes and stromal reaction on the circumference of tumor mass. (Fig 3) However, an intimate correlation between histological evaluation of immunological capacity and clinical prognosis was not documented and the skin reaction against PPD was also not paralleled to clinical prognosis.

From above results, immunological response of tumor bearing host seems to be weak even in those with small sized lung cancer. (Fig 4)

Ten of these thirteen cases with a small sized lung cancer were clinically discovered from the presence of peripheral nodular shadow on chest xp film but recently early cancer of hilar type has become to be diagnosed owing to the development of diagnostic techniques<sup>9)</sup>.

However, it is extremely difficult to diagnose accurately for small sized shadows although there are a large number of reports with special reference to minimal limit of detectable diameter of abnormal shadows on roentgenogram.

The confirmable finding on chest xp in which lung cancer is accurately diagnosed

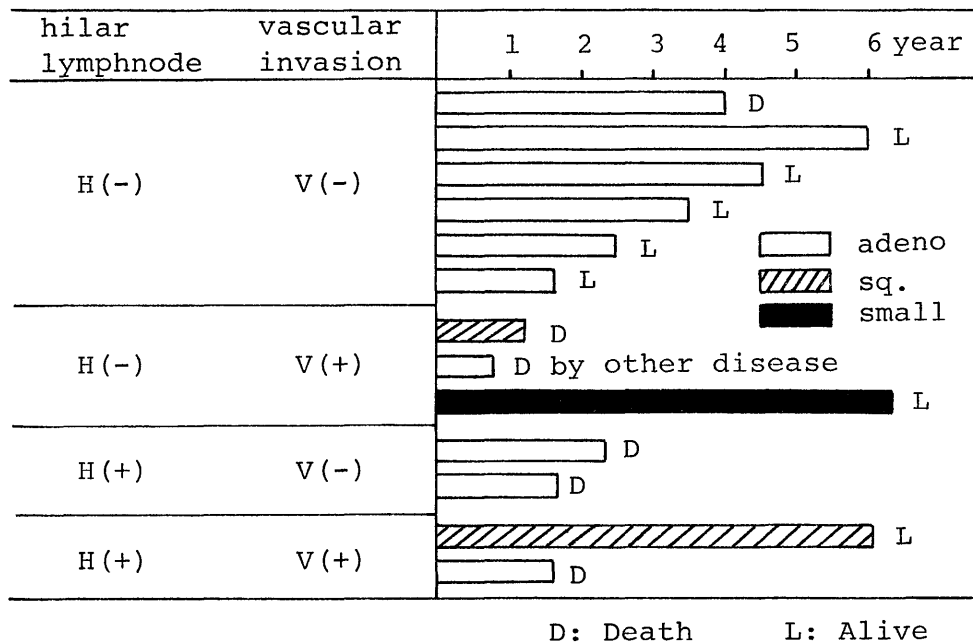


Fig 2. Prognosis related to hilar lymphatic metastasis and vascular invasion

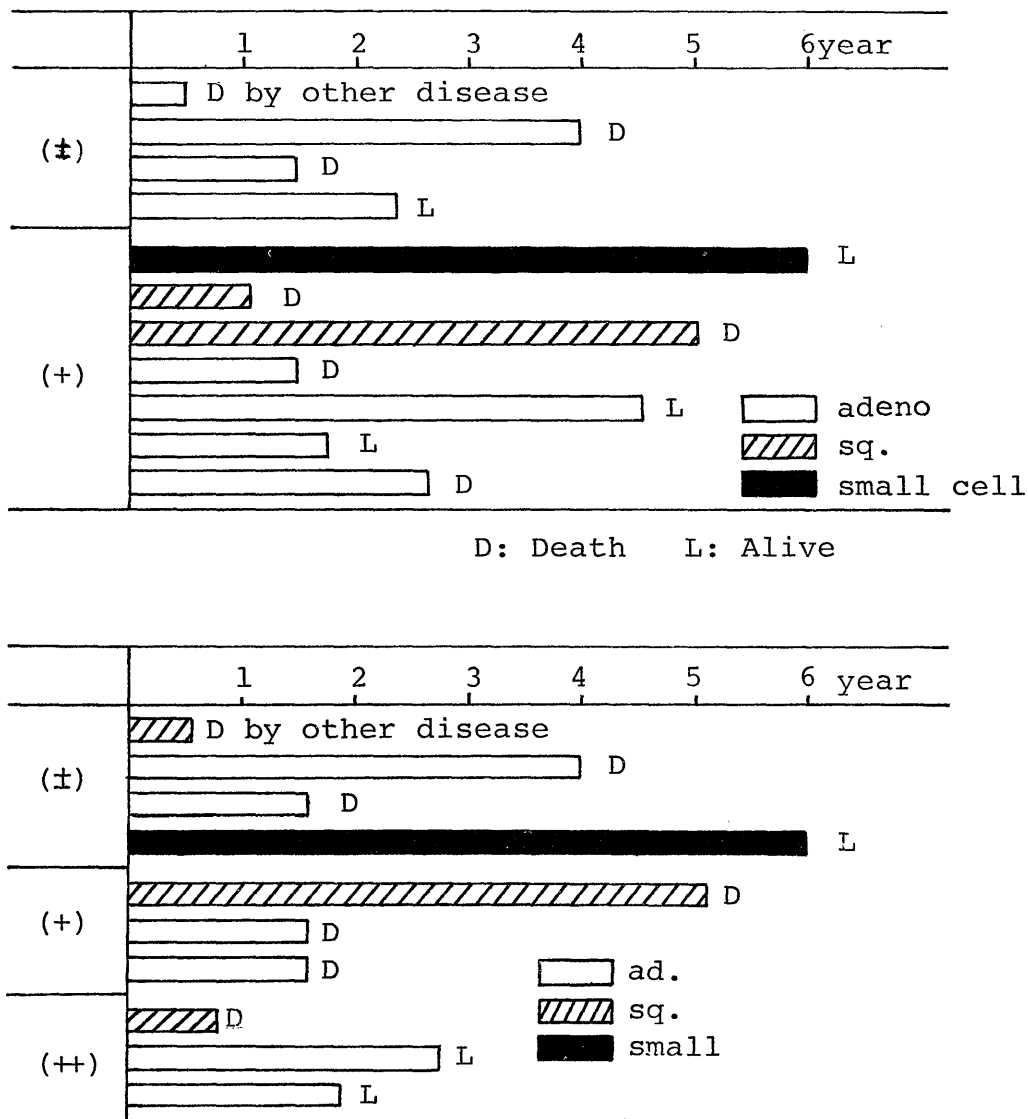


Fig 3. Correlation between prognosis and histological pattern of stromal reaction surrounding tumor mass and degree of histiocytosis in resected lymphnodes

are the irregularity of the surrounding tumor shadow but these finding are revealed on tumor shadow of more than 1.5 cm in diameter. Therefore, the special roentgenologic aspect of lung cancer does not serve as a diagnostic clue in early stage. The early detection of lung cancer demands employment of several kinds of clinical examinations to achieve exact diagnosis against abnormal shadow on chest xp.

The most valuable examination for diagnostic determination of lung cancer exist in cytology by bronchial brushing and transcutaneous needle biopsy. Distant metastasis following surgery was encountered in 5 cases among 11 cases except 2 cases died of other

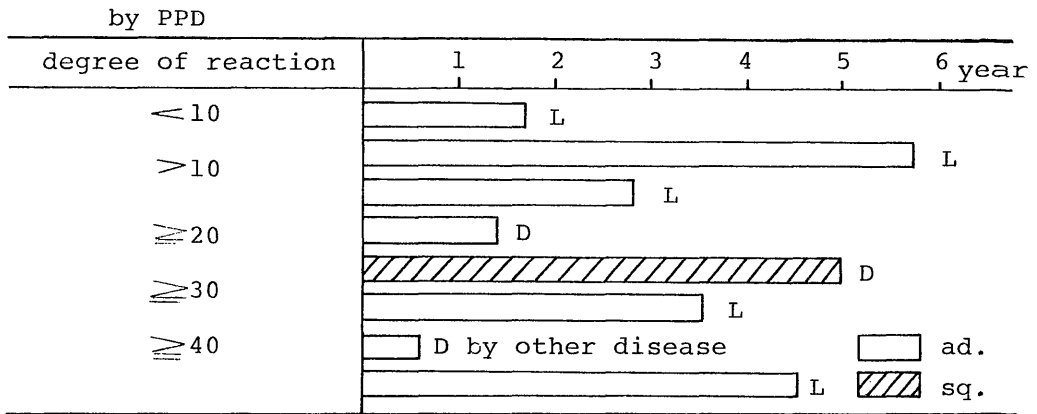


Fig 4. Relationship between prognosis and skin reaction by PPD

diseases. From follow-up study for small sized lung cancer after surgery, it is certified that its prognosis is not necessarily satisfactory and the term of small sized lung cancer of less than 2 cm in diameter is not in accordance with the definition of early cancer in which curability is achieved permanently after surgery. From a practical point of view, the term of early cancer premise that neither local recurrence nor distant metastasis occur following surgical treatment. However, distant metastasis was seen in 45.5 % of these 11 cases except 2 cases who died of other disease unrelated to cancer.

From above results, the achievement of the most satisfactory prognosis appears to be in detection of further smaller sized lung cancer of less than 1 cm in diameter.

However, its prognosis of small sized lung cancer may attribute to histological type and the poorest prognosis seems to be found in those cases with lung cancer of undifferentiated carcinoma.<sup>4)5)6)7)</sup>

Meanwhile, the ratio of tumor growth documented by study of doubling time estimation that tumor growth of undifferentiated carcinoma is the most rapid although that of adenocarcinoma is slow.

However, the high incidence of vascular invasion is seen histologically despite of small sized cancer in adenocarcinoma as well as in undifferentiated carcinoma. As outlined above, the inherent specificities related to its prognosis are also found out in histological pattern. Thereby, it is unable to permit the similar expectance with regard to long term survival among those with small sized lung cancer. To obtain long term survivors for lung cancer after surgery, it is necessary to detect the cancerous lesion of carcinoma in situ although it allows less clinical practice.

In present study for prognostic view of small sized lung cancer, its prognosis is not so fair.

A further study needs for determination as to whether its prognosis for carcinoma of less than 1.0 cm in diameter is excellent or not. Furthermore, immunologic competence in patients with small sized lung cancer was estimated by PPD reaction and histological examination of the degree of sinus histiocytosis in resected lymphnodes and stromal response



in circumference of tumor mass.

However, immunological defensive capacity of tumor bearing host for small sized lung cancer is not well ascertained.

It seems that immunological capacity of tumor bearing host has not been impaired in early stage of lung cancer but the growth rate of tumor has been accelerated by imbalanced condition of immunological defence of host and also surgical intervention has been advocated in early stage to enhance the cure rate.

#### REFERENCES

- 1) WOOLNER, L.B.: Occult carcinoma of the bronchus, : *Dis chest* 37 : 278, 1960.
- 2) PEARSON, F.G.: Experience with the cytologic detection, localization and treatment of radiographically undemonstrable bronchial carcinoma, : *J. Thorac. Cardiovasc. Surg.*, 54 : 371, 1967.
- 3) SHIGETO IKEDA.: New flexible bronchofiberscope.: *J. J. Tracheoesoph.*, 20 : 167, 1969, in Japanese,
- 4) JOHN, W., KIRKLIN, et al : Cell type and other factors relating to prognosis, : *S. G.O.*, 100 : 429, 1955.
- 5) GOLDMAN, K. P. : Histology of lung cancer in relation to prognosis, : *Thorax.*, 20 : 298, 1965.
- 6) HARRY, A.: WELLONS Jr., et al : Prognostic factors in malignant tumors of the lung, : *Ann. Thorac. Surg.*, 5 : 228, 1968.
- 7) JOHN, H. GIBBON Jr.: Factors which influence the long term survival of patients with cancer of the lung. : *Ann. Surg.*, 145 : 637, 1957.